

# Attenuation of Acne Scars Using High Power Fractional Ablative Unipolar Radiofrequency and Ultrasound for Transepidermal Delivery of Bioactive Compounds Through Microchannels

Mario A. Trelles, MD, PhD<sup>1\*</sup> and Pedro A. Martínez-Carpio, MD, PhD<sup>2</sup>

<sup>1</sup>*Instituto Médico Vilafortuny, Cambrils, Tarragona, Spain*

<sup>2</sup>*Clinical Research Unit, IMC-Investiláser, Sabadell, Barcelona, Spain*

**Background and Objective:** To determine the efficacy and safety of a new method for treating acne scarring over a short-term period of 2 months and a long-term period of 6 months.

**Materials and Methods:** Six faces and 13 shoulders or backs for a total of 19 patients were treated, all of which displayed varying degrees of acne scarring, from moderate to severe. A newly developed high-power unipolar fractional ablative radiofrequency technology was used (iPixel™ RF, Alma Lasers, Caesarea, Israel), with acoustic pressure ultrasound guided dermal injection of the PixelTreat Scars preparation (Alma Lasers), through RF Pixel fractionated microchannels. All patients underwent four treatment sessions at 3-week intervals.

**Results:** Significant improvement was observed in scarring, both on the face ( $P < 0.0001$ ), and on the back and shoulders ( $P < 0.0001$ ). After 2 months, the percentage of fading on total scarring was 57% on the face and 49% on the back and shoulders; after 6 months, the percentage increased to 62% on the face, and 58% on the back and shoulders, respectively. Patients reported to be Somewhat Satisfied (16%), Satisfied (53%), and Very Satisfied (31%). No unexpected side effects to the ablation and no hypersensitive reactions to PixelTreat Scars were observed.

**Conclusion:** The bimodal procedure is safe and effective in reducing acne scarring. This represents a new therapeutic alternative of great interest, to be used either as a monotherapy, or in combination with other treatments. *Lasers Surg. Med.* 46:152–159, 2014.

© 2014 Wiley Periodicals, Inc.

**Key words:** acne scars; unipolar radiofrequency; fractional ablation; ultrasound; cosmeceuticals

## INTRODUCTION

Acne is one of the most common dermatological conditions. The possible scarring resulting from it causes serious esthetic and psychological problems in many patients. One of the main aims of acne treatment is to prevent scarring, as once scars are formed, the treat-

ments available are complex, insufficiently effective, and a combination of treatments is often required [1].

Scarring can occur as a result of damage to the skin during the healing of active acne. The skin affected by post-acne scarring has an abnormal contour, with most scars being depressed below the adjacent normal skin. There are two basic types of scar, depending on whether there is a net loss or gain of collagen (atrophic and hypertrophic scars). It is estimated that the vast majority of acne scars are atrophic, and that hypertrophic scars, and keloids are a minority although they are more noticeable. Atrophic scars are divided into three groups (ice pick, boxcar, and rolling). However, in patients with abundant residual scarring, all three types are usually observed and can often be difficult to differentiate [1].

Many treatment methods have been developed for scar improvement, such as cryoslush (with carbon dioxide snow), liquid nitrogen cryopeeling, surgical scar revision, electrosurgical planning, chemical peeling, filler substance implantation, dermabrasion, and laser treatments, among others. These treatments have the disadvantage of being either too mild and ineffective or too aggressive and complicated [2]. Recent studies have shown that some radiofrequency technologies can significantly improve acne scarring [2–5], exhibiting results similar to those of CO<sub>2</sub> fractional laser, and fewer side effects [5].

The aim of this study is to determine the efficacy and safety of a new treatment method for acne scars that combines, in one single procedure, unipolar fractional ablative radiofrequency, and ultrasonic dermal injection of bioactive compounds through perforated acoustic pressure microchannels. Before the study was scheduled, we observed that, in some cases, two treatment sessions

**Conflict of Interest Disclosures:** All authors have completed and submitted the ICMJE Form for Disclosure of Potential Conflicts of Interest and none were reported.

\*Correspondence to: Mario A. Trelles MD, PhD, Instituto Médico Vilafortuny, Fundación Antoni de Gimbernat, Avda Vilafortuny, 31, E43850 Cambrils, Tarragona, Spain.

E-mail: imv@laser-spain.com

Accepted 2 January 2014

Published online 29 January 2014 in Wiley Online Library (wileyonlinelibrary.com).

DOI 10.1002/lsm.22224

objectively achieved some fading after a few weeks, although with modest results. An intensive four-session procedure was selected for the treatment of acne scarring, with the consensus that the final results would be determined after 6 months.

## MATERIALS AND METHODS

### Patients

A prospective study was carried out on 19 patients recruited from scheduled visits to the Instituto Médico Vilafortuny (Cambrils, Tarragona, Spain). The inclusion criteria were as follows: (1) presence of multiple moderate to severe acne scars on the face, back, or shoulders; (2) acceptance of the terms of participation and follow-up through informed consent. The exclusion criteria were as follows: (1) having previously received treatment for scars, except for topical use of pomades and creams; (2) suffering from organic or psychiatric illnesses that might interfere with the evaluation of the results.

### Design

Two groups were formed: group I included six patients who were treated on the face; and group II included 13 patients who were treated on the back or shoulders.

In both groups, four treatment sessions were scheduled, at 3-week intervals. Tolerance to the procedure and short-term side effects were evaluated during the first session, after one hour, on the following day, on the fourth day, on the seventh day, and after the third week, immediately before the second session. The efficacy of the treatment was evaluated at 2 and 6 months after the final session using grades and comparison of digital photographs.

The medical evaluation was performed using the data in the patients' medical records and the photographic records of the injuries before treatment and at 2 and 6 months after the final session. Frontal and bilateral 45 side photographs were taken using the same camera (Nikon CoolpixP50, 12.1 Megapixels, Tokyo, Japan) settings, lighting, and patient positioning.

Patient evaluation was performed through three questionnaires, which were completed after the first treatment session, before the second session and at the end of the trial. The surveys included questions on tolerance, practicability, adverse effects, and evaluation of results. The degree of pain was rated as Nil, Light, Moderate, Severe, and Very Severe. The degree of satisfaction was measured by the terms Very Dissatisfied, Dissatisfied, Somewhat Satisfied, Satisfied, and Very Satisfied, after presenting each patient with photographs taken before and 6 months after treatment.

A single physician, specifically trained to carry out the procedure, was in charge of providing instructions to the patients for the correct interpretation and completion of the questionnaires, applying treatment, performing follow-up examinations and gathering photographic evidence. The physician evaluated the tolerance, complications, and adverse effects of the treatment, but did not take part in the photographic evaluation of treatment efficacy.

### Device and Treatment Protocol

The Legato device (Alma Lasers, Caesarea, Israel) was used for the study protocol.

Legato is a new bimodal system that combines two technologies—fractional ablative microplasma radiofrequency (RF) and acoustic pressure ultrasound (US)—to deliver drugs and bioactive compounds into the dermis. It includes a new high power radiofrequency technology (iPixel™ RF), with different technical and application characteristics to those used to date [6,7]. The device uses the Pixel RF to generate microchannels and provoke thermal damage and fractional ablation. Each microchannel is on average 80–120 μm in diameter and has a depth of 100–150 μm, depending on the RF power settings [7]. After topical application of the preparation into the microchannels, the ultrasound generated by the Impact™ module facilitates penetration into the dermis. The mode of operation is based on mechanical (acoustic) pressure and torques by propagation of the US wave via the sonotrode to the distal horn and the creation of a “hammering” effect. This extracts the liquid from within the microchannels and forces the bioactive compounds to be enhanced under the epidermis–dermis junction through them.

Three hours before treatment, a topical anesthetic containing Lidocaine (Lambdalina®<sup>®</sup>, ISDIN Laboratories, Barcelona, Spain) was applied with a polyethylene occlusive dressing to all patients [8]. Where scars were particularly deep or when patients experienced too much pain during treatment, Mepivacaine anesthetic was injected (Mepivacaina Normon 2%, Normon Laboratories, Madrid, Spain). During treatment, cold air was used (CryoV, Zimmer, Ulm, Germany) on setting 5, which corresponds to a flux speed of 600 L/minute. The nozzle was pointed directly over the tip of the RF hand piece, following its movement. The cold airflow at this speed decreases any pain or discomfort produced by the repeated passes of the RF pixel.

The Pixel RF and the US (Impact) hand piece are built into a console that also houses the software controlling the operation of both modules. The RF hand piece has a removable single-use wheel tip in which multiple needle-like electrodes are placed. The hand piece emits a unipolar RF, producing a high-density microplasma discharge, which creates microscopic perforations on the skin. During the procedure, the wheel is rolled over the skin, controlled by the action of the hand piece trigger. When the rolling wheel is applied firmly to the skin, an electrical discharge occurs, passing to the interior of the skin, with most of the thermal effects taking place in the dermis.

The electrical RF current passes through the dermis in search of the opposite electrode, according to the principles of RF mechanisms of action. When the electrical passage is interrupted, the RF energy is absorbed, producing heating effects due to absorption [6]. However, when the RF wheel tip is rolled over the skin without pressure, with minimal contact between the needles, and the epidermis, microplasma sparks are produced. This microplasma causes

subtle peeling of the superficial keratin layer covering the epidermis. Moreover, the microplasma effect is intended to create microchannels in the epidermis as a consequence of the contact with the RF needle-like electrodes that discharge a high amount of electrical energy.

During the treatment, two criss-cross passes of the wheel tip are performed, that is, four passes of the RF multiple unipolar electrodes, creating a multiple dense microperforation in the epidermis. After this action is completed, the bioactive compounds are applied, followed by application of the ultrasound module (Impact).

The “hammering” effect produced by the sonotrode enables the transfer of the bioactive compounds to the area previously treated with the RF pixel roller, thus increasing the penetration of the compounds into the skin. The ultrasound is perpendicularly applied to the skin surface, in continuous contact with it, in a circular (concentric–eccentric) motion, both with and without pressure. The time allocated to the procedure is set according to the size of the area to be treated. Treatment is carried out for a period of 4–6 minutes, according to the size of the lesion, to enable the transepidermal penetration of the compounds.

The RF Pixel was set at a power of 60 W. The Impact ultrasound device has a pulse modulation control that emits an output power of 40 W, with impacts ranging from 10% to 100% in intensity. The output frequency is 27.5 kHz, with variables between 10 and 100 Hz (acoustic pressure pulse vibration rate per second). The Impact US parameters on the console screen are expressed in intensity percentages (%) between 0% and 100%. The pulse rate is expressed in Hz (1/T).

In the case of deep atrophic scar tissue, RF treatment was initiated by rolling the wheel tip, with four criss-cross passes firmly pressing the tissue, followed by another four criss-cross passes without pressure, to create microchannels in the epidermis. The first RF passes with pressure were intended to introduce electricity into the dermis, so that the current could have a stimulating effect on tissue and collagen formation. Collagen is developed during the healing of the microwounds formed by electricity absorption, which generates a thermal effect.

When the treatment is finished, a soothing cream (Pixel Relief Soothing Cream, manufactured by GV Cosmetic Ltd., Skula, Petah, tikva Israel for NovaMedical Intl. Ltd.) is applied to the treated areas, as part of the protocol recommended by the manufacturers. The patients are then instructed to apply a moisturizing cream to the treated areas twice a day as a maintenance treatment.

### Bioactive Compounds

The cosmetic preparation PixelTreat Scars (Alma Lasers) is applied. The product is specifically formulated by the manufacturer for the treatment of scars. The preparation contains molecules with keratolytic, whitening, and anti-inflammatory effects, as well as liposome-encapsulated peptides, which act upon the collagen, matrix metalloproteinases (MMPs), and specific enzymes. The

ingredients include allantoin, bisabolol, sodium hyaluronate, glycosaminoglycans, dipotassium glycyrrhizate, vitamin B complex, vitamin C, and low molecular weight peptides (SH-polypeptide 15, Palmitoyl tripeptide 28, Tripeptide 8, and Oligopeptide 8).

### Assessment of Results and Statistical Analysis

All pre- and post-treatment evaluations were carried out on the basis of photographic images viewed on a computer screen. Front and profile photographs of the faces of six patients and images of the backs or shoulders of 13 patients were taken at the three times previously mentioned. The resulting 75 photographs were submitted to three dermatologists not involved in the trial for evaluation. A blinded dermatologist (JAF) viewed the 75 photographs in a random order, while grading the severity of the scars on a 6-point (0–5) scale based on their number and contrast. Three blinded dermatologists (JAF, ALP, and IAI) established a scar fading percentage (from 0% to 100%) at 2 and 6 months, respectively, taking into account the number and intensity of the lesions, with particular consideration of atrophic and hypertrophic scars; for this, the evaluators had the possibility to increase the size of each image.

For facial treatments, 24 pairs of profile photographs were viewed and graded; of these, 12 pairs were taken before and 2 months after treatment, and 12 pairs were taken before and 6 months after treatment, in random order, with no knowledge of the time elapsed between them. Following the same procedure, 26 pairs of back or shoulder photographs were also viewed and graded.

The results obtained for the face and back/shoulders were analyzed separately and independently from one another. To verify the existence of attenuation after 6 months, the average values of the 6-point (0–5) grading scale were compared using the Mann–Whitney *U* test. The attenuation percentages achieved were calculated based on the average ratings of the three evaluators. The results at 2 and 6 months were compared using the Wilcoxon signed-rank test. The calculations were performed using SPSS v.13.0 for Windows, and statistical significance was established for values of  $P < 0.05$ .

## RESULTS

The study included 19 patients, of whom 14 were women and five were men (age range 22–53 years, mean age 35.2 years, and Fitzpatrick skin types II–IV).

### Efficacy Results on the Face

The average values on the 6-point (0–5) grading scale were 3.64 before treatment and 1.89 at 6 months, showing significant reduction in scarring ( $P < 0.0001$ ). Table I shows the attenuation percentages for overall scarring on each corresponding half face, according to the experts. The averages percentages of the evaluators JAF, ALP, and IAI were 58.3%, 55.0%, and 56.7% at 2 months and 62.5%, 62.5%, and 61.7% at 6 months, respectively. Therefore, an average attenuation of facial acne scarring of 56.7% at 2 months and 62.2% at 6 months can be established,

**TABLE I. Attenuation Percentages for Total Scars Observed on the Left and Right Half Faces of Six Patients, According to Three Independent Dermatologists (JAF, ALP, and IAI)**

Patient	Side	2 months			6 months		
		JAF (%)	ALP (%)	IAI (%)	JAF (%)	ALP (%)	IAI (%)
1	Right	30	50	40	40	40	30
1	Left	50	40	40	30	40	40
2*	Right	60	70	60	90	80	80
2*	Left	70	60	60	80	80	90
3	Right	50	40	40	50	60	50
3	Left	30	30	40	40	30	40
4	Right	60	50	60	70	60	60
4*	Left	90	80	80	90	80	90
5	Right	40	30	30	30	40	40
5	Left	50	40	60	50	50	40
6*	Right	80	90	90	90	90	90
6*	Left	90	80	80	90	100	90
Mean		58.3	55.0	56.7	62.5	62.5	61.7

The photographs taken at 2 and 6 months were compared, in random pairs, with those taken before the treatment.

\*Cases shown in photographs.

showing a trend for improvement at 6 months without reaching the predetermined statistical significance value ( $P=0.098$ ). Out of six patients, one claimed to be Somewhat Satisfied, three Satisfied, and two Very Satisfied.

Figures 1–3 show the results achieved on the faces corresponding to patients 2, 4, and 6 of Table I. The fading achieved in these cases was greater than 80% according to the three evaluators.

#### Efficacy Results on the Back/Shoulders

The average values on the 6-point (0–5) grading scale were 3.15 before treatment and 1.77 at 6 months, showing a significant reduction in scarring ( $P < 0.0001$ ). Table II shows the attenuation percentages for overall scarring on the backs and shoulders according to the experts. The

averages percentages of the evaluators JAF, ALP, and IAI were 50.8%, 46.9%, and 50.0% at 2 months, and 56.9%, 60.0%, and 58.4% at 6 months, respectively. The average attenuation was 49.2% at 2 months, and 58.4% at 6 months, showing a significant improvement at the sixth month in comparison to the second month ( $P = 0.0022$ ). Out of the 13 patients, two claimed to be Somewhat Satisfied, seven Satisfied, and four Very Satisfied.

Figures 4 and 5 show the results on the back and shoulders corresponding to patients 2, 5, 8, and 10 of Table II, with a fading percentage greater than 70%.

#### Tolerance, Adverse Effects, and Complications

During procedures on the face, the pain was considered to be Light (two patients), Moderate (three patients), and Severe (one patient). During procedures on the back and

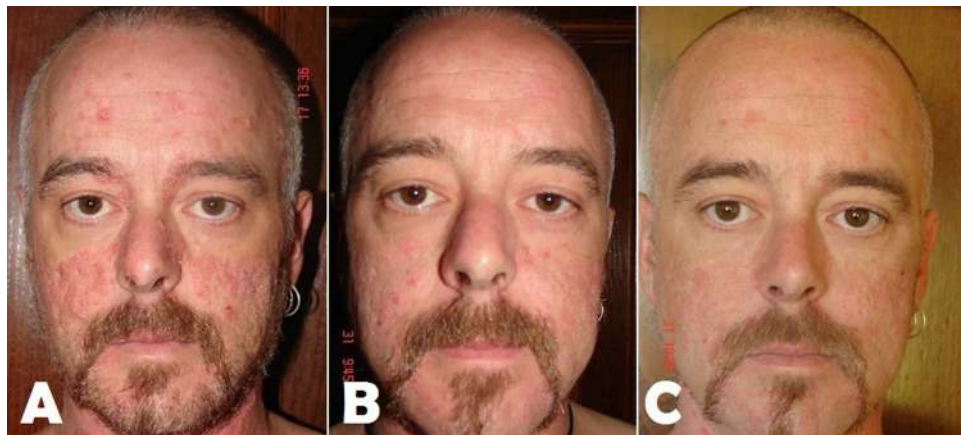

Fig. 1. Patient number 2 (Table I). Long-term evolution atrophic and hypertrophic scars (A), with average fading greater than 60% after 2 months (B), and 80% after 6 months (C).

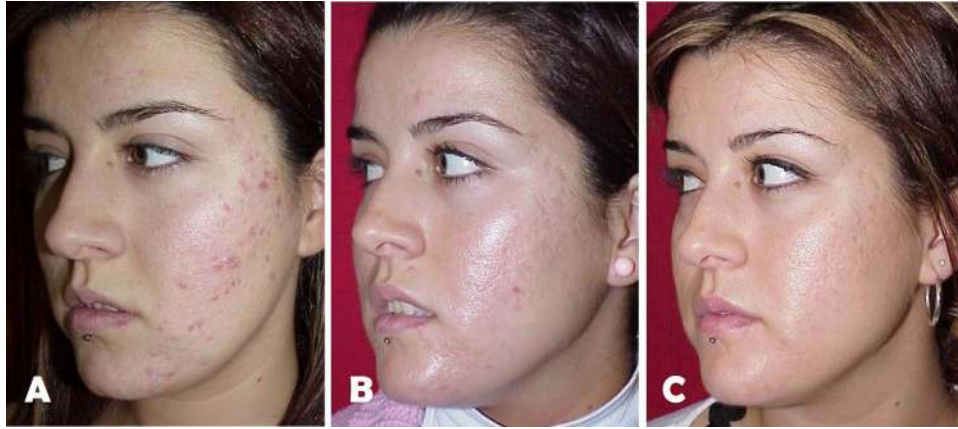

Fig. 2. Patient number 4 (Table I). Hypertrophic scarring, some of which, inflamed, was also treated (A). The improvement at 2 months is evident (B), with minimal residual atrophic scarring at 6 months (C).

shoulders, the pain was considered to be Light (five patients), Moderate (six patients), and Severe (two patients). In the surveys, some patients claimed to have experienced “prickling” electric shocks when applying the RF. At the end of the

procedure, and one hour later, erythema and edema with varying degrees of intensity depending on the case and the areas treated were observed, which for all patients persisted until the following day and had practically disappeared by the fourth day. During the application of ultrasound, cases of epidermal detachment were confirmed, which resulted in very thin scabs that were visible on the fourth day in five cases, and minimally persistent on the seventh day in two cases. At the third week, no adverse effects were observed in the treated areas. During the follow-ups, no cases of hyperpigmentation, hypopigmentation, atrophy or other long-term side effects were observed.

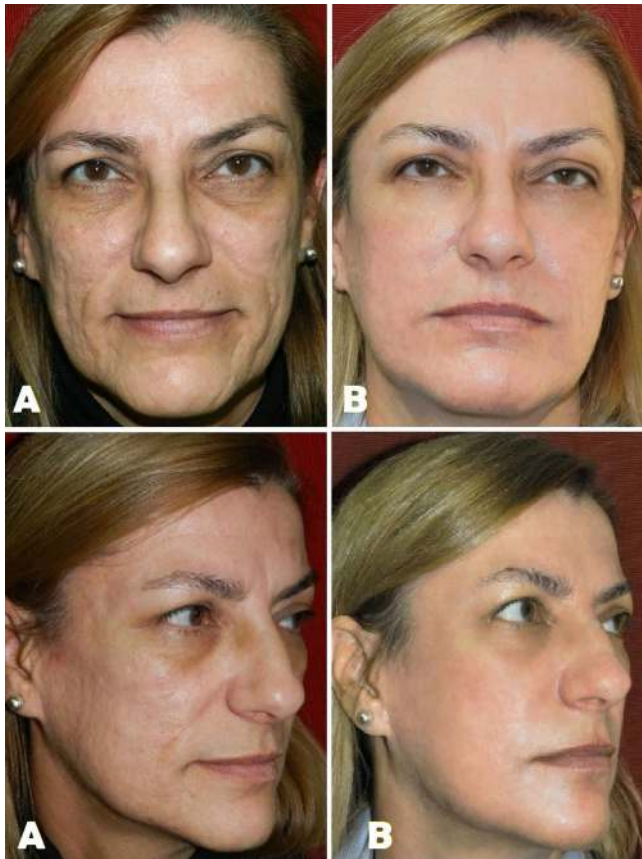

Fig. 3. Patient number 6 (Table I). Atrophic scars (A), which had practically disappeared by the end of the trial (B). This example is very representative of the effect on skin rejuvenation and the reduction of wrinkles that are achieved, in addition to the improvement of scarring.

## DISCUSSION

The results show the global percentage of scar reduction based on photographs, with no distinction made between atrophic and hypertrophic scars, or between subgroups of atrophic scars. Reduction was observed in all types of scars. With regards to the intensity of the scars, that is, the contrast between the depth and elevation in relation to the surrounding skin, a higher reduction was observed in hypertrophic scars. However, a greater number of atrophic scars ceased to be visible in the comparative photographs. Among the atrophic subgroups, ice pick scars had a higher reduction percentage than box scars. For reasons that have yet to be determined, there was variable efficacy within the same types of scarring. The effect is achieved before 2 months, improving after 6 months. Although not complete, attenuation appears to be definite, with no signs of relapse of hypertrophic scars, at 6 months. The patients' high level of satisfaction is due to the realistic expectations of success established prior to the start of the treatment, and the fact that they were shown the before/after photographic results.

According to our information, this is the first study that evaluates the use of Pixel RF for the treatment of acne scars, and also the first to use the Pixel Treat Scars formula recommended by the manufacturer. The procedure was well tolerated and no hypersensitivity reactions to the

**TABLE II. Attenuation Percentages for Total Scars Observed on the Back or Shoulders of 13 Patients, According to Three Independent Dermatologists (JAF, ALP, and IAI)**

Patient	2 months			6 months		
	JAF (%)	ALP (%)	IAI (%)	JAF (%)	ALP (%)	IAI (%)
1	40	40	50	50	40	50
2*	70	80	80	80	90	80
3	40	60	40	50	60	60
4	50	40	40	40	50	60
5*	60	50	70	70	80	60
6	40	30	30	30	50	50
7	60	50	70	60	70	70
8*	70	80	70	80	70	80
9	50	40	50	60	60	50
10*	60	40	40	70	70	60
11	40	30	30	40	50	50
12	50	40	40	60	50	50
13	30	30	40	50	40	40
Mean	50.8	46.9	50.0	56.9	60.0	58.4

The photographs taken at 2 and 6 months were compared, in random pairs, with those taken before the treatment.

\*Cases shown in photographs.

cosmetic preparation were observed. The evolution during the early post procedural period was similar to that observed by Suh et al. [9] and by Issa et al. [10,11], which is attributable to the fractional ablation produced by the

Pixel RF module and the application of ultrasound. The improvement is achieved early (within 2 months), and increases at a lower rate up to the medium term (6 months).

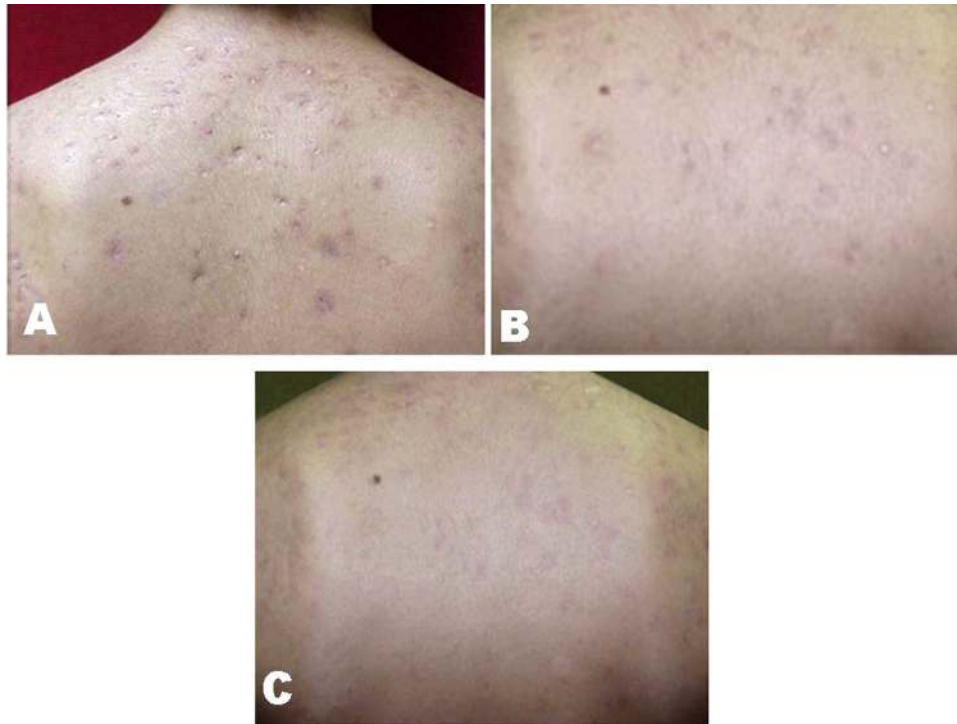


Fig. 4. Patient number 2 (Table II). Atrophic scarring on the back, some of which very depressed, the majority being superficial (A). The improvement is clear at 2 months (B), with the majority having cleared by the 6-month evaluation (C).

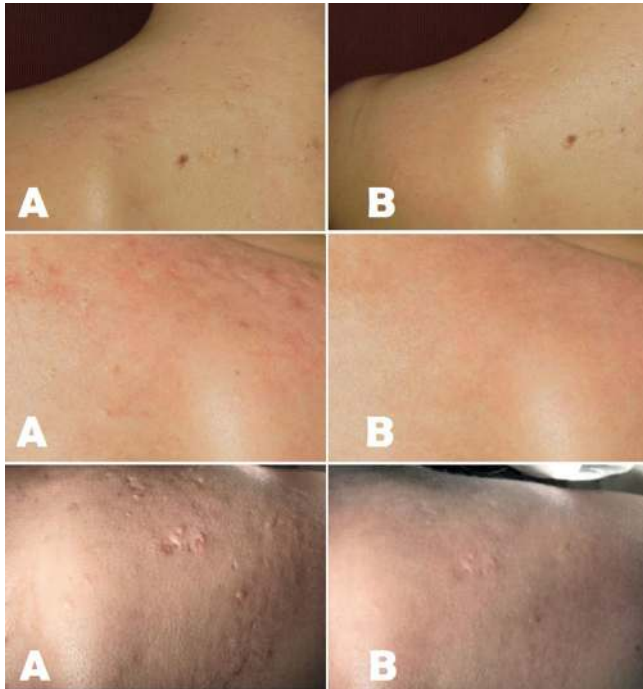

Fig. 5. Patients number 5, 8, and 10 (Table II). Treated areas corresponding to the shoulder and shoulder-blade regions. Atrophic and hypertrophic scarring can be observed (A), where the less pronounced scars disappear completely, and fading of the more severely pronounced scars occurs. Results at the end of the trial (6 months) (B).

Different radiofrequency methods on their own have been very effective in reducing facial acne scarring, with clear advantages over other methods, according to the researchers [2–6]. Three previous studies have evaluated the efficacy of Legato in the treatment of striae distensae [9,10] and hypertrophic scars [11]. The method of applying the Pixel RF was similar (not sufficiently detailed), but the Impact module was used to inject platelet rich plasma, retinoic acid, and triamcinolone, respectively. The results in both cases were surprising, striae were diminished by more than 60% [9] and hypertrophic scars practically disappeared [11].

Although our study does not allow us to differentiate which part of the effect is attributable to the RF, the ultrasound or the cosmetic preparation, we consider that the effect is primarily due to the new RF method used and the trauma caused by the ultrasound—both acoustic and related to fluid pressure—through the microchannels. In the limited published knowledge on Pixel RF, it is noteworthy that, in other types of scars—not caused by acne—the results are just as satisfactory, regardless of whether they are injected with retinoic acid, platelet rich plasma or triamcinolone [9–11]. In a previous split face type study including 14 patients (28 half faces), we showed that injecting a very similar cosmetic to that used in this trial using the same Impact technology increased pinpoint bleeding and the formation of larger and more numerous thin scabs during the postoperative stage after applying

the fractional carbon dioxide laser. This greater skin reaction, attributable to acoustic trauma and the “hammering” effect, may lead to a greater increase in the formation of new collagen in the medium term [12].

In this case, only the clinical results attributable to a sum of effects were evaluated: thermal damage, acoustic trauma, fluid pressure and flow through microchannels, and the properties of a cosmetic injected into the dermis. Pixel Treat Scars was used because its primary components, also found in other cosmetics from the same manufacturer, have proven effective at reducing fine lines and improving skin texture [12]. Although it was not the objective of this study, the photographs show that the treated area is clearly rejuvenated, with a more homogeneous skin texture and a significant esthetic improvement. In the patient surveys, this esthetic improvement was accepted by 18 of the 19 patients.

Literature on scar reduction using radiofrequency is relatively scarce on the Medline database, however the information that can be found coincides in determining its efficacy [2–5,7,8,13]. Ablative laser resurfacing using CO<sub>2</sub> or Er:YAG lasers are mentioned to have an efficacy of 25% to 90% when treating acne scars and is considered the “gold” standard [14]. However, postoperative erythema, infection, scarring, and pigment disorders are not uncommon complications [14]. Radiofrequency, especially in combination with other methods, can achieve aesthetic results which are presented as comparable to those achieved with ablative lasers [2–5,7,8,13], without the limitations that the skin phototype involve and avoiding long standing erythema and post-inflammatory hyperpigmentation [14,15]. The procedure, described in detail to help facilitate future research, represents an innovation of great clinical interest with regards to possible treatments for acne scarring. The efficacy/safety profile of the treatment itself is very positive, and it can also be useful as a complement to other treatments more specific for each type of scar.

## REFERENCES

1. Fabbrocini G, Annunziata MC, D'Arco V, De Vita V, Lodi G, Mauriello MC, Pastore F, Monfrecola G. Acne scars: Pathogenesis, classification and treatment. *Dermatol Res Pract* 2010;2010:893080. Epub 2010 Oct 14. DOI: 10.1155/2010/893080.
2. Ramesh M, Gopal MG, Kumar S, Talwar A. Novel technology in the treatment of acne scars: The matrix-tunable radiofrequency technology. *J Cutan Aesthet Surg* 2010;3:97–101.
3. Gold MH, Biron JA. Treatment of acne scars by fractional bipolar radiofrequency energy. *J Cosmet Laser Ther* 2012;14:172–178.
4. Taub AF, Garretson CB. Treatment of acne scars of skin types II to V by sublative fractional bipolar radiofrequency and bipolar radiofrequency combined with diode laser. *J Clin Aesthet Dermatol* 2011;4:18–27.
5. Zhang Z, Fey Y, Chen X, Lu W, Chen J. Comparison of a fractional microplasma radiofrequency technology and carbon dioxide fractional laser for the treatment of atrophic acne scars: A randomized split-face clinical study. *Dermatol Surg* 2013;39:559–566.
6. Trelles MA, Velez M, Allones I. “Easy Dressing”: An economical, transparent nonporous film for wound care after laser resurfacing. *Arch Dermatol* 2001;137:674–675.

7. Shin MK, Park JM, Lim HK, Choi JH, Baek JH, Kim HJ, Koh JS, Lee MH. Characterization of microthermal zones induced by fractional radiofrequency using reflectance confocal microscopy: A preliminary study. *Lasers Surg Med* 2013;45:503–508.
8. Krueger N, Sadick NS. New-generation radiofrequency technology. *Cutis* 2013;91:39–46.
9. Suh DH, Lee SJ, Lee JH, Kim HJ, Shin MK, Song KY. Treatment of striae distensae combined enhanced penetration platelet-rich plasma and ultrasound after plasma fractional radiofrequency. *J Cosmet Laser Ther* 2012;14:272–276.
10. Issa MC, de Britto Pereira Kassuga LE, Chevrant NS, do Nascimento Barbosa L, Luiz RR, Pantelao L, Vilar EG, Rochael MC. Transepidermal retinoic acid delivery using ablative fractional radiofrequency associated with acoustic pressure ultrasound for stretch marks treatment. *Lasers Surg Med* 2013;45:81–88.
11. Issa MC, Kassuga LE, Chevrant NS, Pires MT. Topical delivery of triamcinolone via skin pretreated with ablative radiofrequency: A new method in hypertrophic scar treatment. *Int J Dermatol* 2013;52:367–370.
12. Trelles MA, Leclère FM, Martínez-Carpio PA. Fractional carbon dioxide laser and acoustic-pressure ultrasound for transepidermal delivery of cosmeceuticals: A novel method of facial rejuvenation. *Aesthetic Plast Surg* 2013;37:965–972.
13. Oh IY, Ko EJ, Kim H, Koh HJ, Park WS, Mun SK, Kim BJ, Kim MN. Facial scar treated with an intradermal radiofrequency device. *J Cosmet Laser Ther* 2013 Oct 17 [Epub ahead of print]. DOI: 10.3109/14764172.2013.854632
14. Asilian A, Salimi E, Faghih G, Dehghani F, Tajmirriahi N, Hosseini SM. Comparison of Q-switched 1064nm Nd:YAG laser and fractional CO<sub>2</sub> laser efficacies on improvement of atrophic facial acne scars. *J Res Med Sci* 2011;16:1189–1195.
15. Lee SJ, Kang JM, Chung WS, Kim YK, Kim HS. Ablative non-fractional lasers for atrophic facial acne scars: A new modality of erbium:YAG laser resurfacing in Asians. *Lasers Med Sci* 2013; [Epub ahead of print]. DOI: 10.1007/s10103-013-1372-8