

ORIGINAL RESEARCH REPORTS

Comparative efficacy of intense pulsed light for different erythema associated with rosacea

JIANJUN LIU¹, JUNLIAN LIU¹, YINGYUN REN², BIN LI¹ & SHICHAO LU¹

¹Department of Dermatology, 306 Hospital of PLA, Beijing, P. R. China and ²Department of Dermatology, 306 Clinical College of Anhui Medical University, Anhui, P. R. China

Abstract

Objective: To compare the efficacy of intense pulsed light (IPL) (540–950nm) in treating different erythema associated with rosacea. **Methods:** Thirty-two patients with erythematotelangiectatic rosacea (ETR) ($n = 16$) and papulopustular rosacea (PPR, $n = 16$) were recruited. Three treatments of IPL (540–950nm) were administered on the face at 3-week intervals. Clinical improvement in erythema was independently assessed by two dermatologists using a quartile grading scale [0, $\leq 25\%$ improvement (poor); 1, 26–50% improvement (fair); 2, 51–75% improvement (good); and 3, 76–100% improvement (excellent)]. Patient satisfaction was evaluated using a 10-point visual analog scale (VAS: 0, lowest; and 10, highest). **Results:** Thirty patients were involved in this study. All patients showed improvement in erythema after three sessions of IPL (540–950nm) treatment. Based on physician's assessment, the overall clinical improvement in PPR group was significantly higher (mean \pm SD of PPR group, 2.167 ± 0.748 vs. ETR group, 1.400 ± 0.541 ; $P = 0.003$) and patient satisfaction was also higher in PPR group (mean \pm SD of PPR group, 6.867 ± 1.457 vs. ETR group, 5.600 ± 1.502 ; $P = 0.026$). The proportion of patients showing $> 75\%$ clinical improvement among PPR group was also higher than that among ETR group (5/15 and 0/15, respectively; $P = 0.021$). Side effects were minimal and transient (erythema and/or edema) for patients. **Conclusions:** IPL (540–950nm) is a safe and effective treatment for rosacea-associated erythema, especially for perilesional erythema.

Key Words: erythema, intense pulsed light, rosacea

Introduction

Rosacea is common inflammatory facial dermatoses affecting primarily fair-skinned Caucasians. Usually, it has four recognized subtypes: erythematotelangiectatic rosacea (ETR), papulopustular rosacea (PPR), phymatous rosacea, and ocular rosacea (1). Facial erythema is one of main clinical features of rosacea, which affects the appearance and has important psychosocial effects. Any discussion of facial erythema in rosacea must first differentiate perilesional erythema from persistent facial erythema (1). Perilesional erythema is dependent solely on association with inflammatory lesions, which is common in PPR (2,3). However, persistent facial erythema is fixed and usually diffuse, to some degree independent of inflammatory lesions, which is common in ETR (2,3).

Various laser and light-based devices have been used for the treatment of erythema and telangiectasias associated with rosacea (4). At present, pulsed dye

laser (PDL) and intense pulsed light (IPL) are typically used to treat facial erythema in ETR. Although a randomized, controlled, single-blind, split-face trial demonstrated no significant difference between PDL and IPL treatment for ETR (5), IPL had some advantages over PDL such as larger spot size and fewer adverse events. Its therapeutic effect was reported to sustain for at least 6 months (6). In this study, we compared the efficacy of IPL (540–950nm) in treating different erythema associated with rosacea.

Materials and methods

Study patients

This study was a prospective quasi-trial and approved by the Ethics Committee of PLA 306 Hospital. Patients were recruited from dermatology clinics in our department from May 2011 to December 2012. All patients gave informed consent prior to participation in this

Correspondence: Shichao Lu, MD, Department of Dermatology, 306 Hospital of PLA, 9 Anxiang North Rd. Chaoyang District, Beijing 100101, P. R. China. Tel: + 86-010-66356984. Fax: + 86-010-64876056. E-mail: lvshichao@sina.com

(Received 25 May 2014; accepted 13 August 2014)

ISSN 1476-4172 print/ISSN 1476-4180 online © 2014 Informa UK, Ltd.
DOI: 10.3109/14764172.2014.957218

study. Inclusion criteria were as follows: age of ≥ 18 years, mild to moderate PPR and ETR. Exclusion criteria were as follows: age of < 18 years, any previous treatment with laser or light-based devices for rosacea, known photodermatoses or photosensitivity, taking photo-sensitizing pharmaceuticals, pregnancy, topical treatments with corticosteroids, metronidazole or calcineurin inhibitors during the previous 2 weeks, and systemic treatments with antibiotics (minocycline) or retinoids during the prior 2 months.

Thirty-two patients were enrolled (8 men and 6 women; age range: 18–47 years—median, 35.8). The disease duration of rosacea was 5.1 years (range, 1–20). All patients were assessed and classified according to Fitzpatrick skin phototype (Fitzpatrick skin phototype III–V).

Of the thirty-two enrolled patients, two patients withdrew from the study due to difficulty in attending follow-up visits.

Treatment procedures

Patients' baseline data were collected by the technician. The Lovely II system (Alma Laser Ltd, Israel) emits IPL (540–950nm) through the Advanced Fluorescence Technology (AFT) handpieces. The 540-nm cutoff filter was used throughout. The pulse width was 12 msec, the spot size was 6.4cm², and the energy density was 10–12J/cm². Post-treatment cooling was provided using ice pack. Patients were treated three times at 3-week intervals. Other topical or systemic treatments that could affect erythema were not permitted. They were also recommended to avoid overexposure to sunlight and to use a broad-spectrum sunscreen after treatment. Patients were free to withdraw from the study at any time and for any reason.

Treatment assessment

Photographs were taken by the same technician at baseline, before each treatment session, and 3 weeks after the third treatment. Two dermatologists assessed the clinical improvement in the severity of erythema using a quartile grading scale [0, $\leq 25\%$ improvement (poor); 1, 26–50% improvement (fair); 2, 51–75% improvement (good); and 3, 76–100% improvement (excellent)] (7). Patients were asked about their overall rates of satisfaction using a 10-point visual analog scale (VAS: 0, lowest; and 10, highest) (7). These evaluations were performed 3 weeks after the third treatment.

Statistical analysis

Physician assessments and patient satisfaction between both groups were analyzed using *t*-test. The proportion of patients showing $> 75\%$ clinical improvement between both groups was compared

using Fisher's exact test. All statistical analyses were carried out by manual calculation. Statistical significance was defined as $P < 0.05$.

Results

Efficacy of therapy

Thirty patients completed this study (18 men and 12 women) (Table I).

Clinical improvement in erythema was assessed by two dermatologists by comparing the photographs taken before and after treatment (Figures 1 and 2). The erythema improvement score of PPR group was significantly higher than that of ETR group (mean \pm SD of PPR group, 2.167 \pm 0.748 vs. ETR group, 1.400 \pm 0.541; $P = 0.003$) (Figure 3). Among PPR group, 10 patients (10/15) showed $> 50\%$ clinical improvement and 5 patients (5/15) achieved $> 75\%$ clinical improvement. However, among ETR group only 5 patients (5/15) showed improvement of $> 50\%$ and no patient experienced $> 75\%$ clinical improvement. The proportion of patients with $> 75\%$ clinical

Table I. Summary of patient characteristics after three sessions of IPL (540–950nm).

Patient	Sex/age (years)	Type of rosacea	Fitzpatrick skin type	Improvement grade	Patient satisfaction
1	M/47	PPR	IV	3	9
2	M/32	PPR	IV	2	7
3	M/44	PPR	IV	3	8
4	M/37	ETR	V	1	5
5	M/24	ETR	IV	2	6
6	M/46	ETR	IV	1	4
7	M/45	ETR	IV	1.5	6
8	F/46	PPR	III	3	9
9	F/35	PPR	III	2.5	7
10	F/18	PPR	III	1	5
11	M/29	ETR	IV	0.5	3
12	F/26	ETR	III	2	7
13	M/43	ETR	IV	1.5	6
14	M/28	PPR	IV	1.5	5
15	M/35	PPR	IV	2	7
16	F/24	PPR	III	2	6
17	F/20	ETR	III	1.5	5
18	M/48	ETR	V	2	8
19	F/33	ETR	III	1	4
20	M/27	PPR	IV	1	5
21	M/38	PPR	IV	2.5	8
22	F/42	ETR	III	1.5	6
23	M/45	ETR	V	2	7
24	M/34	ETR	IV	1	5
25	M/31	PPR	V	1.5	6
26	F/37	ETR	IV	0.5	4
27	F/40	PPR	III	3	8
28	F/32	PPR	III	1.5	5
29	M/41	PPR	V	3	8
30	F/43	ETR	IV	2	8

ETR, erythematotelangiectatic rosacea; PPR, papulopustular rosacea.

Improvement grade (mean value) was independently assessed by two dermatologists by comparing the photographs of patients before and after treatment.

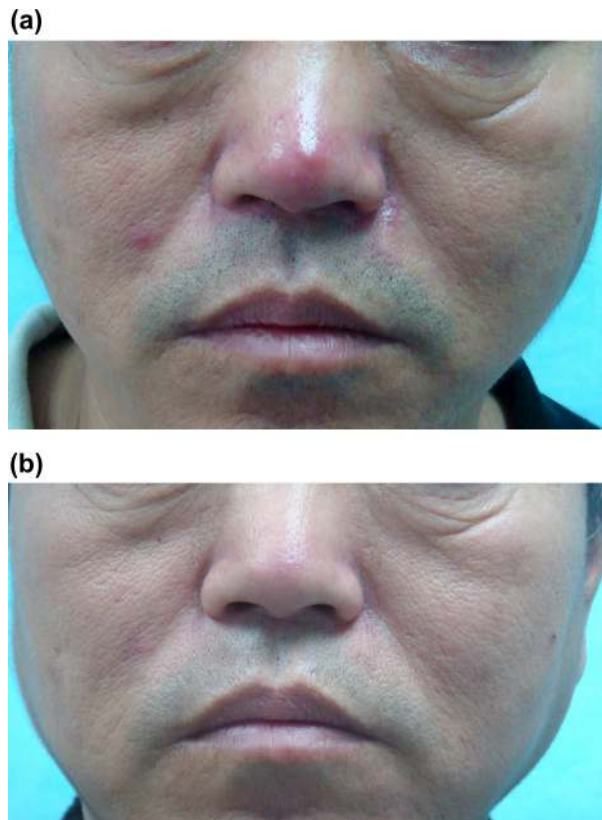


Figure 1. PPR: (a) Before treatment; (b) after three IPL treatments.

improvement among PPR group was also higher than that among ETR group (5/15 and 0/15, respectively; $P = 0.021$).

In addition, the degree of satisfaction of the patients revealed that PPR group had a significantly higher satisfaction score (mean \pm SD of PPR group, 6.867 ± 1.457 vs. ETR group, 5.600 ± 1.502 ; $P = 0.026$).

Adverse events

None of the patients showed any noticeable side effects, such as purpura, bullae, infection, hyperpigmentation, and atrophic scarring, except for transient erythema and/or edema that resolved within a few days.

Discussion

Several underlying pathogenic mechanisms may contribute to varying degrees in facial erythema of rosacea. Current research supports that augmented innate immune response and neurovascular/neuroimmune dysregulation are pivotal components of erythema development in rosacea (3). Other factors appear to contribute to facial erythema of rosacea, including stratum corneum permeability barrier impairment and photo damage (8).

IPL can improve facial erythema by effectively ablating abnormal dilation vessels and reducing extravascular leakage of inflammatory mediators (6).

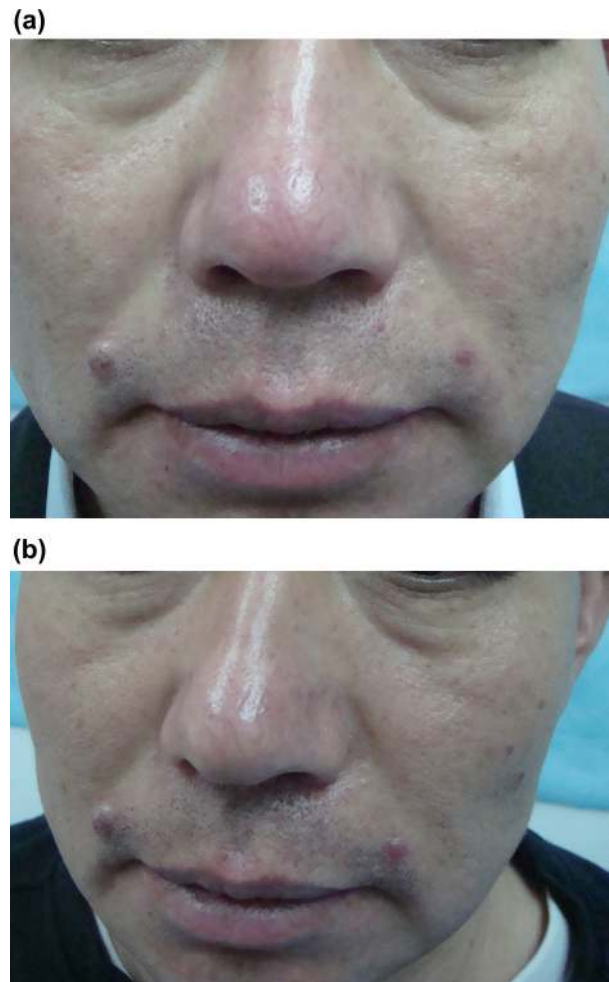


Figure 2. ETR: (a) Before treatment; (b) after three IPL treatments.

Till now, a few studies about evaluating the efficacy of IPL treatment in rosacea have been reported, but their results were quite different. In a pilot study, a 30% decrease in blood flow, a 29% decrease in the area of telangiectasia, and a 21% decrease in erythema intensity was found after five IPL sessions (9). In our study, based on physician's and patient's assessment the clinical improvement score in erythema of the PPR group was higher than that of ETR group, the proportion of

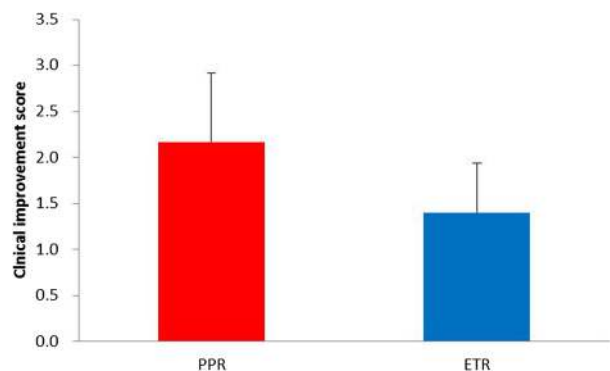


Figure 3. Erythema improvement score of PPR group and ETR group.

patients with >75% clinical improvement among PPR group was also higher than that among ETR group. We speculated that reduction in overall erythema severity of IPL related primarily to a decrease in perilesional erythema. Although IPL might reduce persistent facial erythema, this activity was modest at best in most cases. It was probably due to persistent facial erythema involved with more factors, such as augmented innate immune response, altered vascular response, increased cathelicidin-derived peptides, dermal matrix degradation, and angiogenesis (10–13).

In terms of adverse events, IPL (540–950nm) treatment for facial erythema was generally tolerable and safe. Apart from transient post-treatment erythema and edema, other side effects, such as purpura, bullae, infection, hyperpigmentation, and atrophic scarring, were not observed.

The major limitations of our study were the small sample size and lack of objective assessment tool in the analysis of efficacy. Large clinical studies are needed to compare the efficacy of IPL in treating different erythema associated with rosacea.

In conclusion, IPL (540–950nm) is a safe and effective treatment for rosacea-associated erythema. It can reduce perilesional erythema more significantly than persistent facial erythema. Our study suggests that IPL treatment is a good choice for the treatment of perilesional erythema.

Declaration of interest: The authors report no declarations of interest. The authors alone are responsible for the content and writing of the paper.

References

1. Wilkin J, Dahl M, Detmar M, Drake L, Liang MH, Odom R, et al. Standard grading system for rosacea: report of the National Rosacea Society Expert Committee on the classification and staging of rosacea. *J Am Acad Dermatol.* 2004;50:907–12.
2. Del Rosso JQ. Advances in understanding and managing rosacea: part 1: connecting the dots between pathophysiological mechanisms and common clinical features of rosacea with emphasis on vascular changes and facial erythema. *J Clin Aesthet Dermatol.* 2012;5:16–25.
3. Del Rosso JQ. Advances in understanding and managing rosacea: part 2: the central role, evaluation, and medical management of diffuse and persistent facial erythema of rosacea. *J Clin Aesthet Dermatol.* 2012;5:26–36.
4. Butterwick KJ, Butterwick LS, Han A. Laser and light therapies for acne rosacea. *J Drugs Dermatol.* 2006;5:35–39.
5. Neuhaus IM, Zane LT, Tope WD. Comparative efficacy of nonpurpuragenic pulsed dye laser and intense pulsed light for erythematotelangiectatic rosacea. *Dermatol Surg.* 2009;35:920–928.
6. Papageorgiou P, Clayton W, Norwood S, Chopra S, Rustin M. Treatment of rosacea with intense pulsed light: significant improvement and long-lasting results. *Br J Dermatol.* 2008;159:628–632.
7. Kim TG, Roh HJ, Cho SB, Lee JH, Lee SJ, Oh SH. Enhancing effect of pretreatment with topical niacin in the treatment of rosacea-associated erythema by 585-nm pulsed dye laser in Koreans: a randomized, prospective, split-face trial. *Br J Dermatol.* 2011;164:573–579.
8. Dirschka T, Tronnier H, Folster-Holter R. Epithelial barrier function and atopic diathesis in rosacea and perioral dermatitis. *Br J Dermatol.* 2004;150:1136–1141.
9. Mark KA, Sparacio RM, Voigt A, Marenus K, Sarnoff DS. Objective and quantitative improvement of rosacea-associated erythema after intense pulsed light treatment. *Dermatol Surg.* 2003;29:600–604.
10. Yamasaki K, Di Nardo A, Bardan A, Murakami M, Ohtake T, Coda A, et al. Increased serine protease activity and cathelicidin promotes skin inflammation in rosacea. *Nat Med.* 2007;13:975–980.
11. Steinhoff M, Buddenkotte J, Aubert J, Sulk M, Novak P, Schwab VD, et al. Clinical, cellular, and molecular aspects in the pathophysiology of rosacea. *J Investig Dermatol Symp Proc.* 2011;15:2–11.
12. Schwab VD, Sulk M, Seeliger S, Nowak P, Aubert J, Mess C, et al. Neurovascular and neuroimmune aspects in the pathophysiology of rosacea. *J Investig Dermatol Symp Proc.* 2011;15:53–62.
13. Yamasaki K, Gallo RL. Rosacea as a disease of cathelicidins and skin innate immunity. *J Investig Dermatol Symp Proc.* 2011;15:12–15.